



Successful Bone Marrow Recovery After an Immunoablative Regimen With Autologous Cord Blood Transplant in a Child With Idiopathic Severe Aplastic Anemia: A Case Report

Monika Rosa, Kornelia Gajek, Małgorzata Salamonowicz-Bodzioch, Monika Mielcarek-Siedziuk, Jowita Frączkiewicz, Tomasz Jarmoliński, Igor Olejnik, and Marek Ussowicz*

Department of Paediatric Bone Marrow Transplantation, Oncology, and Hematology, Wrocław Medical University, Wrocław, Poland

ABSTRACT

Background. Aplastic anemia is a rare disease that manifests as bone marrow failure. The current treatment options include immunoablative therapy or allogeneic hematopoietic stem cell transplantation. We report a successful immunoablative regimen with autologous umbilical cord blood (auto-UCB) transplant in a 3-year-old boy with severe aplastic anemia.

Case Report. The immunoablation procedure consisted of 5×3.75 mg/kg antithymocyte globulin (Thymoglobulin) (total 18.75 mg/kg), methylprednisolone for 4 days, and cyclosporine A. The patient received auto-UCB containing 0.3×10^5 CD34⁺ cells per kilogram of body weight. Recovery of leukocyte count above 1000/ μ L was reached on post-transplant day +39, and recovery of granulocytes above 500/ μ L was reached on day +40. The final regular transfusions of packed red blood cells and platelet concentrate were performed on day +55. The complications that occurred in the post-transplant period were nausea, diarrhea, septic fever, and hepatic abscess formation. Post-transplant immunosuppression with cyclosporine A was discontinued 17.5 months after auto-UCB, and the patient remained in complete remission with normal blood counts and bone marrow morphology.

Summary. Auto-UCB transplantation without chemotherapy conditioning can be considered a therapeutic option for children with stored cord blood cells.

APLASTIC anemia (AA) is a rare but life-threatening hematologic disorder that was first reported by Paul Ehrlich in 1885; however, the etiopathogenesis of the disease remains unclear. The hallmark of AA is pancytopenia caused by hypoplasia or aplasia of the bone marrow (BM) as a consequence of direct damage by chemical or physical factors as well as constitutional or acquired genetic defects, leading to hematopoietic failure and autoimmune phenomena that cause damage to stem cells. Direct BM damage can be caused by iatrogenic factors such as chemotherapy and radiation therapy and, less commonly, by chemical exposure, such as to benzene [1]. In approximately 5% of AA cases, constitutional genetic defects are found [2,3]. A predisposition to AA has been reported in telomere biology disorders, such as dyskeratosis congenita, caused by the impairment of telomere repair (telomerase enzyme complex dysfunction) or the inadequate protection of telomeres (shelterin protein

defects). A rare but very important entity among the constitutional bone marrow failure syndromes is Fanconi anemia, which is caused by deficient repair of DNA double-strand breaks and is associated with hypersensitivity to chemotherapy [4]. In approximately half of patients with AA, the cause cannot be identified, but the bone marrow destruction is immune mediated. Autoimmunity can be triggered by alterations in antigens modified by drugs, chemical agents, and viral activation receptors and, consequently, can lead to activation of the immunologic cascade and damage to BM

*Address correspondence to Marek Ussowicz, Department of Pediatric Bone Marrow Transplantation, Oncology, and Hematology, Wrocław Medical University, Borowska 213, 50-556 Wrocław, Poland. Tel: +4871-7332700; Fax: +4871 7332709. E-mail: ussowicz@tlen.pl

cells via activated T lymphocytes that produce interferon gamma, tumor necrosis factor, and interleukin 2 [3–6]. The diagnostic criteria of severe AA (SAA) according to the international European Working Group–SAA require a cellularity below 25% in BM biopsy specimens, an absolute neutrophil count (ANC) $< 0.5 \times 10^9/L$, a platelet count $< 20 \times 10^9/L$, and a reticulocyte count $< 20 \times 10^9/L$ [4]. Very severe AA is diagnosed when all criteria for SAA are met and when the neutrophil count is $< 0.2 \times 10^9/L$ [4]. Hematopoietic stem cell transplant (HSCT) from an HLA-identical sibling donor is the method of choice for the treatment of SAA in children. Patients without sibling donors undergo immunosuppressive (IS) therapy or HSCT from a matched unrelated donor [4,7–9]. We report a rare case of successful IS therapy with autologous umbilical cord blood (auto-UCB) HSCT in a 3-year-old boy with SAA.

CASE REPORT

A 3-year-old boy without a relevant past medical or a family history was admitted to the pediatric ward because of fever and otitis. After 1 week of antibiotic treatment, he developed a skin rash and petechiae. The laboratory test results showed leukopenia, thrombocytopenia, and anemia. The BM biopsy specimen and trephine biopsy specimen showed hypocellular bone marrow without signs of normal hematopoiesis. Viral infections (HIV, Epstein-Barr virus, cytomegalovirus, ParvoB19, hepatitis A/B/C) were excluded as well as autoimmune causes of leukopenia (negative antinuclear antibodies, perinuclear antineutrophil cytoplasmic antibody, cytoplasmic antineutrophil cytoplasmic antibody, normal C3 and C4). Chromosomal breakage tests excluded Fanconi anemia, and the patient showed no clone of paroxysmal nocturnal hemoglobinuria. The boy's DNA, which was isolated from blood mononucleated cells, was screened with Next Generation Sequencing panel TruSight One (Illumina, San Diego, Calif, United States); this test revealed no pathogenic variants or variants of unknown significance in the genes involved in the pathogenesis of constitutional BM failure syndromes. The patient received prophylaxis against opportunistic infections (posaconazole, trimethoprim/sulfamethoxazole, and acyclovir), and decontamination of the digestive tract with colistin was started. HLA typing of the patient and his family showed full HLA compatibility between the patient and his 7-month-old sister, but because of large differences in body weight, the sister was not eligible for stem cell donation within a reasonable time. The parents reported the deposition of the patient's auto-UCB unit containing 0.5×10^6 CD34⁺ cells, which was 0.3×10^5 CD34⁺ per kilogram. In lieu of the disparity in weight between the allogeneic donor and the recipient, a decision was reached that the IS protocol and autologous cord blood cell transplant would be performed. The IS procedure was performed according to the European Working Group guidelines and consisted of 5×3.75 mg/kg antithymocyte globulin (total 18.75 mg/kg), intravenous methylprednisolone for 4 days and cyclosporine A (CSA). After IS therapy, the autologous cord blood cells were thawed and reinfused into the patient. Hematologic reconstitution was stimulated by filgrastim starting on the day of transplant. Recovery of leukocyte count above 1000/ μ L was reached on post-transplant day +39, and recovery of granulocytes above 500/ μ L was reached on day +40 (Fig 1). The final regular transfusions of red blood cells and platelets were performed on days +55 and +50, respectively. The complications that occurred in the post-transplant period were septic fever, diarrhea, nausea, and hepatic abscess formation. On post-transplant day +1, the patient developed an *Enterobacter cloacae* blood stream infection, and

removal of the central venous catheter was performed. Fever of unknown origin lasted from day +10 to day +45 after transplant until neutrophil recovery. The child was treated with broad-spectrum antibiotic therapy (including tigecycline followed by linezolid) and liposomal amphotericin B, and because of the suspicion of influenza, oseltamivir was added starting on day +20. During the diagnostic work-up, on post-transplant day 14, abdominal ultrasonography revealed liver infiltrates that progressed in number by day +49. Abdominal and chest computed tomography scans were performed on day +52 and demonstrated 10 hypodense foci 5 to 35 mm in size surrounded by a halo in the liver. Microbiological cultures and serologic tests excluded listeriosis, cryptosporidiosis, tuberculosis, *Entamoeba histolytica* and fungal (*Aspergillus*, *Candida*, *Cryptococcus*) infections. Empirical therapy for unidentified liver abscesses (meropenem, gentamicin, metronidazole, caspofungin) was started. The diagnostic liver biopsy was performed on day +129, and the collected samples did not show any relevant changes. During follow-up, the liver demonstrated recovery as well as the disappearance of the previously observed abscesses. The patient underwent bone marrow biopsies on days 129 and 377, and the specimens revealed normal BM cellularity and hematopoiesis. Post-transplant immunosuppression with CSA was continued and tapered until it was stopped 17.5 months after HSCT. The patient's complete blood counts 20 months after HSCT showed normal values, and the child does not currently show any signs of disease.

DISCUSSION

Despite the nonmalignant character of SAA, leaving this disease untreated is fatal because of infectious complications, and effective therapy should be immediately initiated. Allogeneic HSCT is associated with treatment-related mortality due to acute or chronic graft-vs-host disease (GVHD), and surviving patients are at risk of developing late sequelae. The actual 3-year survival rate after transplant is estimated to be 73% in adults [10]. The results of SAA therapy in children are superior to those in the adult population, but the role of IS therapy in recent years has decreased in favor of upfront transplantation from matched unrelated donors because of the high IS failure rate with event-free survival of 33% [11]. The overall survival is higher in children treated with HSCT from a matched sibling than from an unrelated donor (91% vs 96%; P =not significant), but the long-term outcome data and especially the survival-free rate from chronic GVHD have not been properly analyzed [11,12]. The choice of donor, grafting material, conditioning regimen, and immunosuppressive therapy affect the outcome after HSCT and are responsible for the variability in the reported results. In nonmalignant diseases, the preferred stem cell source is the bone marrow, but transplantation with peripheral blood stem cells is gaining popularity because of the convenience of graft processing. Cord blood is another source of stem cells for HSCT, and it has been successfully used since the first successful transplant of allogeneic UCB in 1989 [13]. To date, more than 35,000 UCB transplants have been performed, and UCB is commonly used in the pediatric population [14]. UCB has unique properties separating it from other types of HSCT. CD34⁺/CD38[–] hematopoietic stem cells from UCB can proliferate more rapidly and generate larger numbers of progeny cells than BM cells [15,16]. This phenomenon can be explained by the long

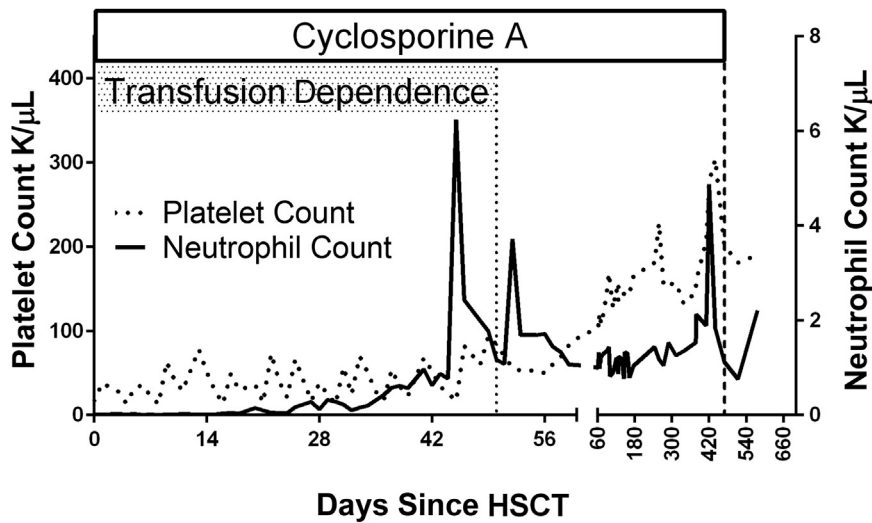


Fig 1. Blood count results and transfusion dependence after IS therapy and auto-UCB HSCT. Periods of transfusion dependence and CSA therapy are marked. auto-UCB, autologous umbilical cord blood; CSA, cyclosporine A; HSCT, hematopoietic stem cell transplant; IS, immunosuppressive.

telomere length in UCB cells resulting in a great proliferative capacity [17]. UCB contains a low number of hematopoietic progenitor cells and can be associated with an increased risk of graft failure and delayed hematopoietic engraftment; thus, UCB is regarded as a sufficient source of stem cells only for children weighing less than 40 kg [18]. The current recommendations for allogeneic UCB HSCT are 4.9×10^7 total nucleated cells (TNCs)/kg at collection and 3.5×10^7 TNCs/kg at infusion [8]. If the CD34 number in UCB is available, the recommended CD34 dose is 1 log lower than in BM or mobilized peripheral cells [19–21]. The strategies used to overcome the limitations of UCB include ex vivo expansion, infusion of 2 UCB units, cotransplantation with hematopoietic or mesenchymal cells, and HSC priming to enhance homing and engraftment. The role of allogeneic UCB HSCT in SAA is marginal because of the high risk of graft rejection associated with immune-mediated stem cell damage in primary disease and the risk of infections [8,22]. According to EUROCORD data from 1991 to 2006, a total of 19 upfront UCB transplants from related donors were performed: 18 SAA and 1 erythrocytic aplasia, and 16 of 19 patients were alive and well after 4 years of follow-up [12]. Moreover, several unrelated UCB HSCTs were performed among children who failed to respond to IS therapy [18]. One of the largest studies on allogeneic UCB HSCT in SAA included 71 patients (among them, 28 were adults, and the median age was 13 years); the cumulative incidence of platelet engraftment on post-transplant day 180 was 37% (SD, 6%), and the cumulative incidence of neutrophil recovery was 51% in the study group on day 60. Significantly better engraftment was observed in patients who received transplants with a higher TNC dose (over 3.9×10^7 /kg; hazard ratio, 1.5) [17]. Studies analyzing the outcomes of allogeneic UCB HSCT in SAA show an acceptable time to neutrophil engraftment, which can be superior to the time for IS therapy alone. A study in adults with SAA by Yamamoto et al showed that the median time to achieve neutrophil engraftment was 18 days (range, 12–28 days), and the time to

achieve a platelet count over 20×10^9 /L was 42 days (range, 26–64 days) after allogeneic UCB HSCT [23]. A pediatric study on allogeneic UCB HSCT in SAA from 2008 reported that the median time to myeloid engraftment was 25 days (range, 17–59 days) [18]. In another pediatric study by Yoshimi et al, the median times to achieve a neutrophil count $\geq 0.5 \times 10^9$ /L and a platelet count $\geq 50 \times 10^9$ /L were reached after 19 days (range, 12–35 days) and 59 days (range, 39–145 days), respectively [24]. Autologous UCB in AA is an extremely rare procedure because of many limitations. First, autologous UCB collection and storage represent an expensive, nonrefundable procedure that has no established medical indications outside of families with children suffering from malignant neoplasms who potentially require HSCT. The benefit of autologous UCB HSCT in SAA comes from eliminating the risk of the treatment-related mortality associated with GVHD and immunosuppression-induced opportunistic infections. Over the last 20 years, only 11 reports about autologous blood cord transplants have been reported [25]. Interestingly, no significant differences in the outcome of SAA after standard immunoablative therapy or mixed IS/UCB transplantation have been found. In the reported patients after autologous UCB HSCT, neutrophil engraftment was usually observed after 30 days [26]. Conditioning before HSCT in SAA is necessary because historic studies have shown that stand-alone infusion of syngeneic bone marrow does not lead to hematopoiesis recovery in over 70% of treated patients [27]. UCB is a less convenient stem cell source than BM or peripheral blood stem cells, and because of the higher risk of nonengraftment, patients require conditioning. In children with SAA, the effective conditioning protocol before allogeneic HSCT is usually cyclophosphamide based, which is immunosuppressive but nonmyeloablative. In most reports, the autologous HSCTs in children with SAA are preceded by a combination of antithymocyte globulin with steroids and CSA, which can be seen as a step down from typical allogeneic HSCT [27]. This approach offers both a potential curative advantage of the

immunoablation protocol with the addition of viable stem cell infusion and does not expose the patient to chemotherapy, thus reducing the risk of tissue damage and infections due to mucosal injury. The efficacy of autologous UCB HSCT cannot be sufficiently proven in a clinical trial because of the incidental availability of autologous UCB and the extremely low incidence of SAA. The potential risk of treatment failure in the auto-UCB HSCT strategy should not interfere with the preparation of the criterion standard therapy, that is, allogeneic HSCT. The decision regarding the choice of suitable therapy can be based on the patient's condition, but patients without life-threatening complications can be referred for auto-UCB HSCT. A sine qua non condition for referring the patient for auto-UCB is the exclusion of constitutional BM failure syndromes because of the risk of a lack of response and leukemogenesis in cancer susceptibility syndromes. Our clinical experience shows that the post-transplant period can be associated with serious opportunistic infections and that the patient condition needs to be intensively diagnosed and treated in cases of fever. The option of auto-UCB HSCT is unlikely to affect the practical approach for the treatment of SAA, but it is worth considering in patients who have stored autologous UCB material.

ACKNOWLEDGMENTS

This study is supported by a grant provided by "Na Ratunek Dzieciom z Chorobą Nowotworów" Foundation, FNRD.C200.17.002. Supplemental support was provided by Wrocław Medical University statutory grant ST.C200.18.013.

REFERENCES

- [1] Young NS. Aplastic anemia. *N Engl J Med* 2018;379:1643–56.
- [2] Keel SB, Scott A, Sanchez-Bonilla M, Ho PA, Gulsuner S, Pritchard CC, et al. Genetic features of myelodysplastic syndrome and aplastic anemia in pediatric and young adult patients. *Haematologica* 2016;101:1343–50.
- [3] Young NS, Calado RT, Scheinberg P. Current concepts in the pathophysiology and treatment of aplastic anemia. *Blood* 2006;108:2509–19.
- [4] Cancer Trials Ireland. EWOG-SAA-2010. <http://www.cancertrials.ie/cti-trials/ewog-saa-2010/>. 2010 [Accessed 19.06.12].
- [5] Young NS, Barrett AJ. The treatment of severe acquired aplastic anemia. *Blood* 1995;85:3367–77.
- [6] Marsh JC. Hematopoietic growth factors in the pathogenesis and for the treatment of aplastic anemia. *Semin Hematol* 2000;37:81–90.
- [7] Führer M, Rampf U, Baumann I, Faldum A, Niemeyer C, Janka-Schaub G, et al. Immunosuppressive therapy for aplastic anemia in children: a more severe disease predicts better survival. *Blood* 2005;106:2102–4.
- [8] Avery S, Shi W, Lubin M, Gonzales AM, Heller G, Castro-Malaspina H, et al. Influence of infused cell dose and HLA match on engraftment after double-unit cord blood allografts. *Blood* 2011;117:3277–85 [quiz 3478].
- [9] Marsh JCW. Treatment of acquired aplastic anemia. *Haematologica* 2007;92:2–5.
- [10] Locasciulli A, Oneto R, Bacigalupo A, Socie G, Korthof E, Bekassy A, et al. Outcome of patients with acquired aplastic anemia given first line bone marrow transplantation or immunosuppressive treatment in the last decade: a report from the European Group for Blood and Marrow Transplantation. *Haematologica* 2007;92:11–8.
- [11] Dufour C, Veys P, Carraro E, Bhatnagar N, Pillon M, Wynn R, et al. Similar outcome of upfront-unrelated and matched sibling stem cell transplantation in idiopathic paediatric aplastic anaemia. A study on behalf of the UK Paediatric BMT Working Party, Paediatric Diseases Working Party and Severe Aplastic Anaemia Working Party of EBMT. *Br J Haematol* 2015;171:585–94.
- [12] Samarasinghe S, Steward C, Hiwarkar P, Saif MA, Hough R, Webb D, et al. Excellent outcome of matched unrelated donor transplantation in paediatric aplastic anaemia following failure with immunosuppressive therapy: a United Kingdom multicenter retrospective experience. *Br J Haematol* 2012;157:339–46.
- [13] Gluckman E, Broxmeyer HE, Auerbach AD, Friedman HS, Douglas GW, Devergie A, et al. Hematopoietic reconstitution in a patient with Fanconi's anemia by means of umbilical-cord blood from an HLA-identical sibling. *N Engl J Med* 1989;321:1174–8.
- [14] Niederwieser D, Baldomero H, Szer J, Gratwohl M, Aljurf M, Atsuta Y, et al. Hematopoietic stem cell transplantation activity worldwide in 2012 and a SWOT analysis of the Worldwide Network for Blood and Marrow Transplantation Group including the global survey. *Bone Marrow Transplant* 2016;51:778–85.
- [15] Kadereit S, Deeds LS, Haynesworth SE, Koc ON, Kozik MM, Szekely E, et al. Expansion of LTC-ICs and maintenance of p21 and BCL-2 expression in cord blood CD34(+)/CD38(-) early progenitors cultured over human MSCs as a feeder layer. *Stem Cells* 2002;20:573–82.
- [16] Rocha V, Wagner JE, Sobocinski KA, Klein JP, Zhang MJ, Horowitz MM, et al. Graft-versus-host disease in children who have received a cord-blood or bone marrow transplant from an HLA-identical sibling. *N Engl J Med* 2000;342:1846–54.
- [17] Schuller CE, Jankowski K, MacKenzie KL. Telomere length of cord blood-derived CD34+ progenitors predicts erythroid proliferative potential. *Leukemia* 2007;21:983–91.
- [18] Chan KW, McDonald L, Lim D, Grimley MS, Grayson G, Wall DA. Unrelated cord blood transplantation in children with idiopathic severe aplastic anemia. *Bone Marrow Transplant* 2008;42:589–95.
- [19] Hexner EO, Danet-Desnoyers GH, Zhang Y, Frank DM, Riley JL, Levine BL, et al. Umbilical cord blood xenografts in immunodeficient mice reveal that T cells enhance hematopoietic engraftment beyond overcoming immune barriers by stimulating stem cell differentiation. *Biol Blood Marrow Transplant* 2007;13:1135–44.
- [20] Haspel RL, Kao G, Yeap BY, Cutler C, Soiffer RJ, Alyea EP, et al. Preinfusion variables predict the predominant unit in the setting of reduced-intensity double cord blood transplantation. *Bone Marrow Transplant* 2008;41:523–9.
- [21] McKenzie JL, Gan OI, Doedens M, Dick JE. Reversible cell surface expression of CD38 on CD34-positive human hematopoietic repopulating cells. *Exp Hematol* 2007;35:1429–36.
- [22] MacMillan ML, Walters MC, Gluckman E. Transplant outcomes in bone marrow failure syndromes and hemoglobinopathies. *Semin Hematol* 2010;47:37–45.
- [23] Yamamoto H, Kato D, Uchida N, Ishiwata K, Araoka H, Takagi S, et al. Successful sustained engraftment after reduced-intensity umbilical cord blood transplantation for adult patients with severe aplastic anemia. *Blood* 2011;117:3240–2.
- [24] Yoshimi A, Kojima S, Taniguchi S, Hara J, Matsui T, Takahashi Y, et al. Unrelated cord blood transplantation for severe aplastic anemia. *Biol Blood Marrow Transplant* 2008;14:1057–63.
- [25] Georgia A, Christina O, Aikaterini K, Elda I, Anna K, Anna P, et al. Successful long-term hematological and immunological reconstitution by autologous cord blood transplantation combined with post-transplant immunosuppression in 2 children with severe aplastic anemia. *Pediatr Transplant* 2019;23:e13320.
- [26] Sun Y, Liu Z, Xiao J, Liu X, Jiang F, Fan S, et al. Autologous cord blood transplantation in children with acquired severe aplastic anemia. *Pediatr Transplant* 2018;23:e13325.
- [27] Hinterberger W, Rowlings PA, Hinterberger-Fischer M, Gibson J, Jacobsen N, Klein JP, et al. Results of transplanting bone marrow from genetically identical twins into patients with aplastic anemia. *Ann Intern Med* 1997;126:116.